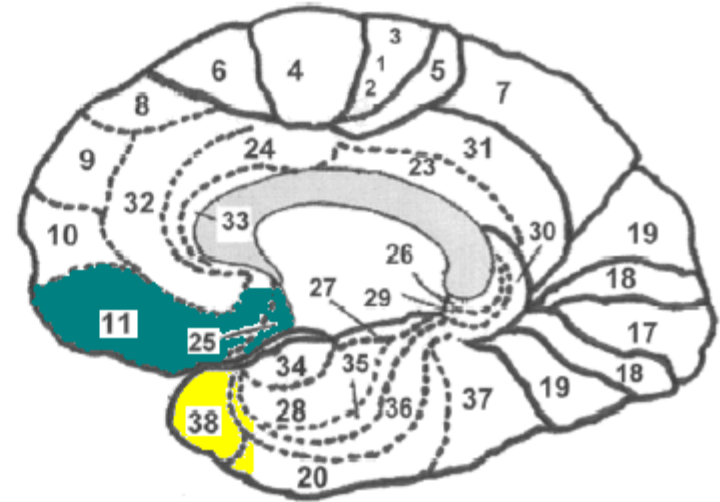
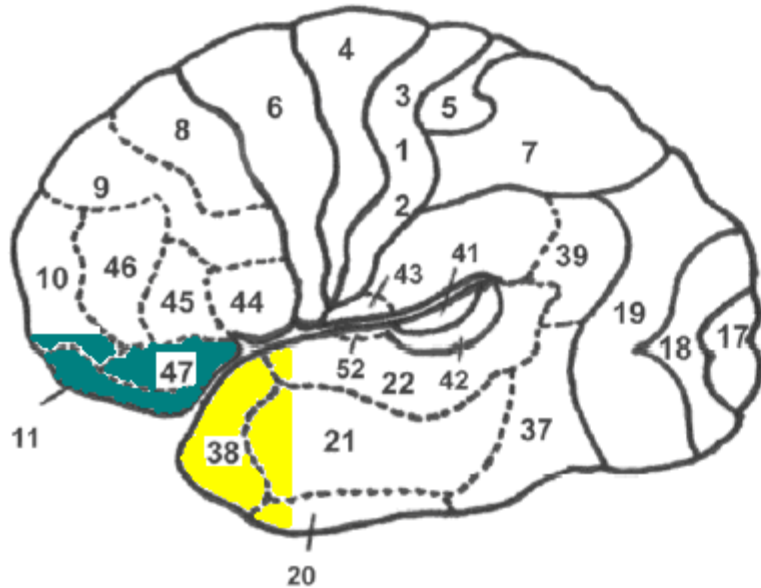


Left lateral surface of the brain

Medial surface of the brain, right hemisphere





(A)  orbitofrontal cortex (OFC) (B)
 anterior temporal lobe (ATL)

Illustration © Valerie E Stone 2009

Figure 1. The brain, with Brodmann areas marked (Brodmann areas are anatomical regions determined by differences in cell structure).

(A) View of the left hemisphere from the outside (called a “lateral view”). Orbitofrontal cortex in this view would include primarily Brodmann area 11, but also area 47 and lower parts of area 10. The anterior temporal lobe in this view would include primarily Brodmann area 38, but also the front-most parts of areas 20-22.

(B) View of the right hemisphere from the center of the brain (called a “medial view”). Orbitofrontal cortex would include Brodmann areas 11, 25 and possibly lower parts of area 32. The anterior temporal lobe in this view would include primarily Brodmann area 38, but also the front-most parts of areas 20 & 36.